

HeartPad: Real-Time Visual Guidance for Cardiac Ultrasound

Steven T. Ford^{1,2*} Ivan Viola^{3,4} Stefan Bruckner⁵ Hans Torp¹ and Gabriel Kiss^{1,6}

¹Norwegian University of Science and Technology, MI Lab and
Department of Circulation and Medical Imaging, Trondheim, Norway

²Høgskolen i Nord-Trøndelag, Norway

³University of Bergen, Norway

⁴Christian Michelsen Research, Norway

⁵Institute of Computer Graphics and Algorithms, Vienna University of Technology, Austria

⁶St. Olavs Hospital, Trondheim, Norway

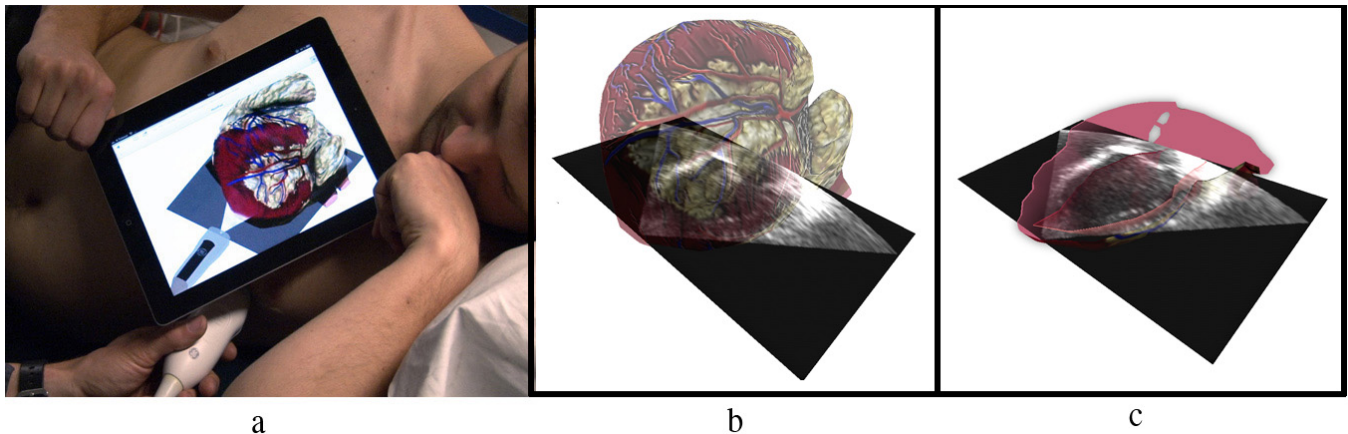


Figure 1: (a) In-situ visual guidance during echocardiographic scanning. (b-c). Combined renderings of the heart's anatomic model and data acquired with ultrasound corresponding to a diagnostic view (i.e. the four chamber view).

Abstract

Medical ultrasound is a challenging modality when it comes to image interpretation. The goal we address in this work is to assist the ultrasound examiner and partially alleviate the burden of interpretation. We propose to address this goal with visualization that provides clear cues on the orientation and the correspondence between anatomy and the data being imaged. Our system analyzes the stream of 3D ultrasound data and in real-time identifies distinct features that are basis for a dynamically deformed mesh model of the heart. The heart mesh is composited with the original ultrasound data to create the data-to-anatomy correspondence. The visualization is broadcasted over the internet allowing, among other opportunities, a direct visualization on the patient on a tablet computer. The examiner interacts with the transducer and with the visualization parameters on the tablet. Our system has been characterized by domain specialist as useful in medical training and for navigating occasional ultrasound users.

CR Categories: I.3.3 [Computer Graphics]: Three-Dimensional Graphics and Realism—Display Algorithms I.3.7 [Computer Graphics]: Three-Dimensional Graphics and Realism—Radiosity;

Keywords: 3D echocardiography, In-situ visualization
acmsiggraph

1 Introduction

Echocardiography is a diagnostic imaging technique dedicated to the investigation of heart diseases. The basic concept is a reconstruction of reflected patterns of acoustic signaling that is directed at a particular object or tissue of interest. This modality has numerous advantages as compared to other radiological imaging modalities. This is because it is a real-time modality which combines several valuable acoustic modalities within one. Also it is inexpensive and does not produce dangerous ionizing radiation.

Medical ultrasound is a very operator-dependent modality. It has problems with physical limitations, such as the speed of sound and the difficulties with penetrating bones and air cavities. Because this modality is acoustically based, it suffers from problems such as speckle noise, and shadows.

Successful utilization of ultrasound is highly dependent on the experience of the examiner. Compared to computerized tomography

*e-mail:stford1@gmail.com

or magnetic resonance imaging, ultrasound images are known to be more challenging for medical students to learn to interpret. In addition to the cognitive load associated with interpreting the image, the examiner has to control the correct positioning of the transducer to ensure that he or she is imaging the correct anatomical area and that the image quality is satisfactory. Therefore, ultrasound became a strong tool for a relatively small group of highly trained medical professionals, who perform ultrasound examinations daily. For the potential occasional users, such as general practitioners, ultrasound is an incredibly useful tool that they are unable to utilize due to image interpretation difficulties.

One way to enable medical ultrasound for occasional use, is to alleviate the examiner from the burden of interpreting the image during the examination. By providing visual guidance through overlays which communicate the structures being imaged, one can greatly improve the understanding of the structural arrangement of tissues during scanning. This is the goal we are addressing in this paper.

Our solution is a guided 2D and 3D visualization where the clinician can relate the ultrasound data to a patient-adapted anatomical mesh-model of a human heart and related anatomical context. The relation and anatomical understanding is achieved through 3D visualization overlays and interaction with the model and data, (such as clipping, viewpoint manipulation etc.) which creates a guide to the image as they scan. To further alleviate the occasional ultrasound examiners from mental data-to-patient registration, we enable the visualization to work in-situ by placing a commodity tablet hardware running the guided visualization on the chest of the patient during the ultrasound examination. This creates the illusion of a virtual window into the patients chest and heart.

These live visual enhancements to the ultrasound image, which are customized to the patient's anatomy, are technologically realized through a unique combination of algorithms and hardware. Thus the main contribution of this paper is the novel system for visual enhancement of echocardiographic examinations. Individual aspects of the proposed system that are novel on its own are:

- patient-specific dynamic 3D heart model driven by landmark tracking
- live ultrasound internet broadcasting
- metaphor of virtual window into human anatomy realized with commodity hardware

Before new contributions are presented, the body of literature that addresses the challenges related to ultrasound image interpretation is discussed in Section 2. The methodology of our data-processing pipeline is presented in Section 3. The implementation of the conceptual pipeline with modern technology is described in Section 4. The results from the technological prototype are demonstrated and discussed in Sections 5 and 6. Finally, the paper points out the limitations of the current state of implementation, draws conclusions and suggest follow-up work in Section 7.

2 Related Work

The effective visualization of 3D ultrasound data has many different aspects. Typically, data is visualized through multiplanar slicing, surface fitting or direct volume rendering [NE93]. Classification is difficult because data sets are fuzzy and typically contain a substantial amount of speckle, noise, and dropout. Initially this issue was addressed with pre-smoothing the original data [SSG95]. More recent approaches have employed variational methods, such as in the work of Fattal and Lischinski [FL01]. Visualization can be further improved by adjusting the opacity along the ray based on which

intensity levels are being intersected by that ray [HRH03]. An ultrasound visualization pipeline including a comparison of state of the art rendering techniques applied to cardiac data is discussed in a recent survey [BSH*12].

Because an ultrasound allows real-time imaging, it is particularly interesting for the clinical investigation of patients with suspected heart failure and cardiac valve disease [DCSF*08]. Hung et al. [HLF*07] give a comprehensive overview of the current applications and challenges of 3D echocardiography.

A main problem is that effective 3D depiction requires sufficiently accurate segmentation which is difficult to achieve during the live procedure. Hence, 3D reconstruction is typically performed offline for the measurement of parameters, as in the system of Varandas et al. [VBS*04]. Berlage et al. [BFGQ96] presented EchoSim, a training system which lets the cardiologist conduct virtual examinations of the human heart based on prerecorded data. Real-time visualizations, however, are typically restricted to basic planar views. In order to integrate 3D information during the procedure, the patient's heart can be registered to a pre-generated model. Pieper et al. [PWB97] used landmark-based registration to a surface model which then augments the slice view with additional contours. Brattain et al. [BVH12] employed tracking of an instrument tip during minimally invasive intra-cardiac procedures to provide additional visual guidance during the ultrasound. Our approach in contrast, uses feature-tracking to enable real-time 3D visual guidance during examinations and does not require additional fiducial markers.

The potential of improving medical procedures by providing additional visual guidance has been extensively studied within the field of augmented reality [KRRB06]. Such information is typically presented using head-mounted displays [HBK07] or projector-based setups [BKK*05]. Sonic Flashlight, introduced by Stetten et al. [SC01; SCT00], uses a half-silvered mirror to depict ultrasound images directly on the patient's body. Bajura et al. [BFO92] used a see-through head-mounted display to integrate ultrasound images into a three-dimensional scene. State et al. [SLG*98] employed a similar setup for ultrasound-guided biopsies. Stdeli et al. [SKR*08] presented information from pre-operative CT images combined with live ultrasound data during radio-frequency ablation of liver tumors. In our approach, we deliberately chose to employ low-cost tablet computers for the presentation of guidance information. This enables clinicians to easily make use of our system that minimally interferes with their workflow.

Abstractions from illustrative visualization have been previously proposed for visual guidance in liver ultrasound examinations. One of these is illustrative cutaway visualization, which can be employed for multimodal visualization of CT with ultrasound [BHW*07]. In addition, for liver ultrasound examination, partitioning into liver lobes is of high diagnostic and treatment relevance. This partitioning can be composited as an illustrative overlay over the ultrasound image through multimodal registration [VNØ*08], or by feature matching between the patient and an anatomical model [ØUG*11]. These works, however, do not suggest any useful scheme how to deal with the dynamic scenario of cardiac examination, which is a central contribution of our work.

3 The HeartPad System

During a typical echocardiographic examination several standard transthoracic views need to be found and imaged by the cardiologist. These include the two, three, four and five chamber views, subcostal and the parasternal views. These views can be seen as cut planes through the heart that go through standard anatomical landmarks. The position and orientation of the ultrasound probe is adjusted interactively, while trying to find these views and achieve

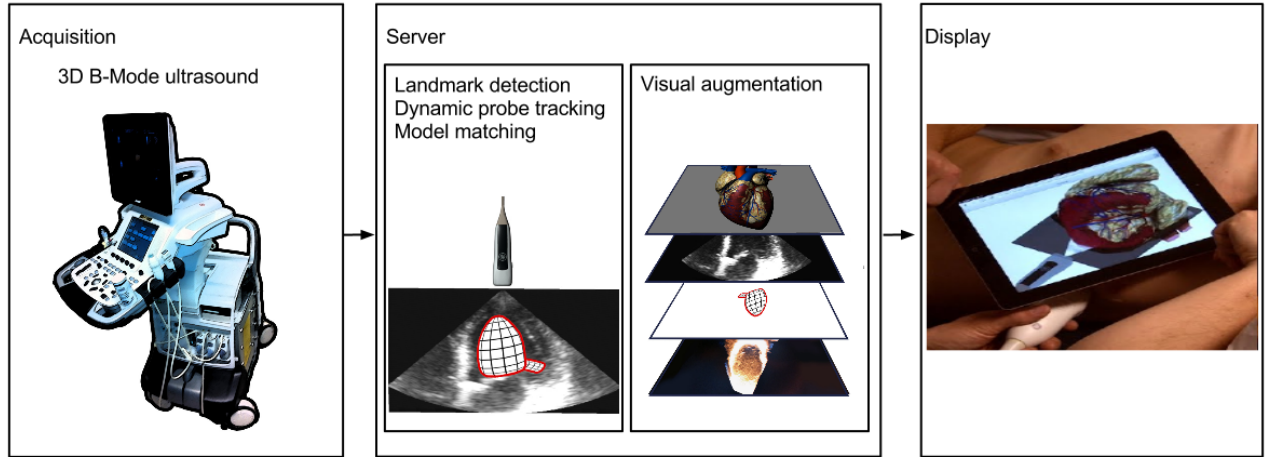


Figure 2: Conceptual overview of our system. The **acquisition** module consists of a high-end cardiac ultrasound scanner. The **server** implements the feature based registration of the virtual space with the real world and generates an augmented image. Finally the **display** of this image can occur either in-situ on the patient’s chest or can be remote.

the optimal image quality. In order to obtain good acquisition quality in the 2D acquisition mode, detailed anatomical knowledge of the heart is required. This information needs to be correlated with the current position and orientation of the probe which defines the imaging plane. Furthermore, since the imaging is carried out through the chest wall, the cardiologist must be careful to avoid the lungs and the ribs, which cause strong attenuation of the ultrasound signal and will lead to artifacts in the final image.

Recently, 3D echocardiography has been deemed suitable for clinical use, as an alternative to 2D echocardiography. This technique allows the acquisition of volumetric datasets in real-time, therefore enabling detailed anatomical assessment of cardiac structure and pathology and adds the ability to slice the heart by any plane in an anatomically appropriate manner. Although this is easier for the non-experts to operate, the relationship between the currently acquired volume and the underlying anatomy is still not explicitly visualized. To overcome these pitfalls we propose a visual guidance system that places a 2D or 3D cardiac acquisition in the proper anatomical context.

3.1 Overview

The conceptual overview of our system is presented in Figure 2. The process starts with the acquisition of 3D cardiac B-mode ultrasound data, which is then streamed to a server module. The server is responsible for generating a composite image, which is streamed to the tablet device or a remote location for display purposes.

3D cardiac acquisitions were taken from the apical window, without ECG triggering, during normal breathing or at end expiratory breath-hold. The depth and angle of the ultrasound sector were adjusted such that the entire left ventricle was covered. In-house developed software was used for real-time streaming of the ultrasound volumes from the scanner to a server computer.

On the server, the position of predefined anatomic landmarks is automatically determined using a feature detection step (Section 3.2). Based on the detected features, the position of the ultrasound slice is dynamically updated according to the probe movement (Section 3.3) and the geometric models are deformed to match the ultrasound data (Section 3.4). A visual augmentation step (Section 3.5)

will generate a composite image that shows the relative position of the current ultrasound slice, with regards to a generic 3D model of the heart. A simplified kinematic model derived from the anatomic landmarks is then applied to the 3D heart model.

The resulting composite image is finally streamed from the server to the tablet via a Wi-Fi connection. Additionally, the tablet will send back to the server commands from the user and its sensor information (e.g. gyri values) that will alter the content of the composite image. The user interface also controls the appearance of different elements in the virtual scene and relies on a touch optimized framework designed for mobile platforms.

The server allows for multiple connections at the same time (i.e. one in-situ tablet and several remote clients, which can be other tablets or even laptop/desktop computers). This offers new opportunities in remote diagnosis of patients in real-time, but can also be used for guidance during the acquisition of ultrasound data (e.g. an expert cardiologist can give remote feedback to a general practitioner or a student on how to improve the quality of the acquired data).

3.2 Anatomic landmarks detection

Anatomic landmarks are necessary in order to be able to align and deform the generic 3D model of the heart towards the current ultrasound volume. Four anatomic landmark points that are identifiable in the 3D B-mode ultrasound data have been defined. As illustrated in Figure 3, these represent the apex of the left ventricle $A(x, y, z)$, the base of the left ventricle $B(x, y, z)$, the middle of the aortic outflow tract $T(x, y, z)$ and the attachment point situated on the anterior wall between the left and right ventricles $V(x, y, z)$. A 4×4 matrix representation of the landmark positions is defined as:

$$L = \begin{bmatrix} A_x & B_x & T_x & V_x \\ A_y & B_y & T_y & V_y \\ A_z & B_z & T_z & V_z \\ 1 & 1 & 1 & 1 \end{bmatrix} \quad (1)$$

The position of the same landmarks has been manually identified on the generic 3D model and is denoted $L_{3D\ model}$.

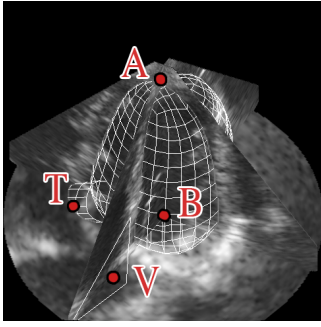


Figure 3: Wire-frame view of the coupled deformable model of the left ventricle, with the four anatomic landmarks depicted as red spheres.

A tracking framework based on an extended Kalman filter is employed to automatically fit a coupled deformable model to the live ultrasound data stream. The coupled model (Figure 3) consists of three structures representing the left ventricle chamber, the left ventricle outflow tract and part of the anterior wall of the right ventricle. Based on the model, the positions of the anatomic landmarks (L_{fit}) are computed for each time step and therefore tracked dynamically [OTR09].

The relation between corresponding landmark points on the 3D model and the ones on the fitted deformable model is given by:

$$L_{fit} = T_{model} \times L_{3D\ model} \quad (2)$$

with T_{model} being a 4×4 homogeneous matrix. The affine transformation T_{model} can be computed as:

$$T_{model} = L_{3D\ model} \times L_{fit}^{-1} \quad (3)$$

3.3 Dynamic probe tracking

In order to track the position and orientation of the probe movement dynamically, an initial registration of the virtual scene with the actual patient, probe and tablet is required. Currently this is manually established by requesting the cardiologist to identify the 4 chamber view (the easiest to image) and by aligning the virtual probe on the tablet with the ultrasound probe.

At this point the user can turn on a dynamic tracking mode, the position of the landmarks is saved as L_{init} . During this mode the patient remains still and therefore the only movement recorded is the probe movement. The affine transformation matrix corresponding to this movement is computed as:

$$T_{tracking} = L_{init} \times L_{fit}^{-1} \quad (4)$$

To keep visual consistency, scaling is ignored and only translation and rotation are accounted for. The final homogeneous tracking matrix is thus:

$$T_{dynamic} = T_{tracking} \cdot \begin{bmatrix} s_x & s_x & s_x & 1 \\ s_y & s_y & s_y & 1 \\ s_z & s_z & s_z & 1 \\ 1 & 1 & 1 & 1 \end{bmatrix} \quad (5)$$

with $[s_x \ s_y \ s_z \ 1]$ being the diagonal values of $T_{tracking}$ and $\cdot /$ denoting element by element matrix division.

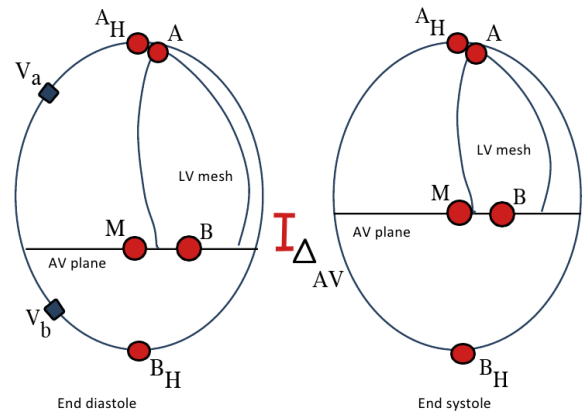


Figure 4: Cross-sectional view of the four chamber, the simplified kinematic model for the whole heart and left ventricle is detailed.

3.4 Model matching

Currently, our system includes a simplified high definition model of the heart including the left ventricle, which is the chamber best imaged with an apical 3D ultrasound, and the outer layer of the heart. Only the end-diastolic case was modelled and therefore both models need to be animated to match the deformation of the structures present in the ultrasound data. The deformation of the coupled model, described in Section 3.2, can be directly transferred to the left ventricle model.

The outer layer of the heart has a different motion pattern. It is assumed to have a constant volume and that the points A_H and B_H are nearly stationary. A simplified kinematic model representing the motion of the mitral annular plane (AV plane) is replicated (Figure 4). The mitral annular plane excursion throughout the heart cycle is given by:

$$\Delta_{AV} = \max(d(A, B)) - d(A, B) \quad (6)$$

with $d(A, B)$ being the distance between the apex and base points on the coupled left ventricle model and $\max(d(A, B))$ occurring at end-diastole.

The mitral annular plane has been identified on the high level 3D model of the heart and all vertices $v_a(x, y, z)$ above it are displaced by:

$$v_a = v_a - \Delta_{AV} \times \frac{d(A_H, \text{proj}(v_a, \overrightarrow{A_H M}))}{d(A_H, M)} \times \widehat{A_H B_H} \quad (7)$$

with proj projecting a point onto a vector, $\widehat{A_H B_H}$ returning the unit vector of $\overrightarrow{A_H B_H}$ and M the intersection point between the mitral annular plane and the vector $\overrightarrow{A_H B_H}$.

The vertices below the plane $v_b(x, y, z)$ are displaced by:

$$v_b = v_b - \Delta_{AV} \times \frac{d(B_H, \text{proj}(v_b, \overrightarrow{B_H M}))}{d(B_H, M)} \times \widehat{A_H B_H} \quad (8)$$

As such, an anatomically correct deformation of both the left ventricle and heart models throughout the heart cycle can be achieved.

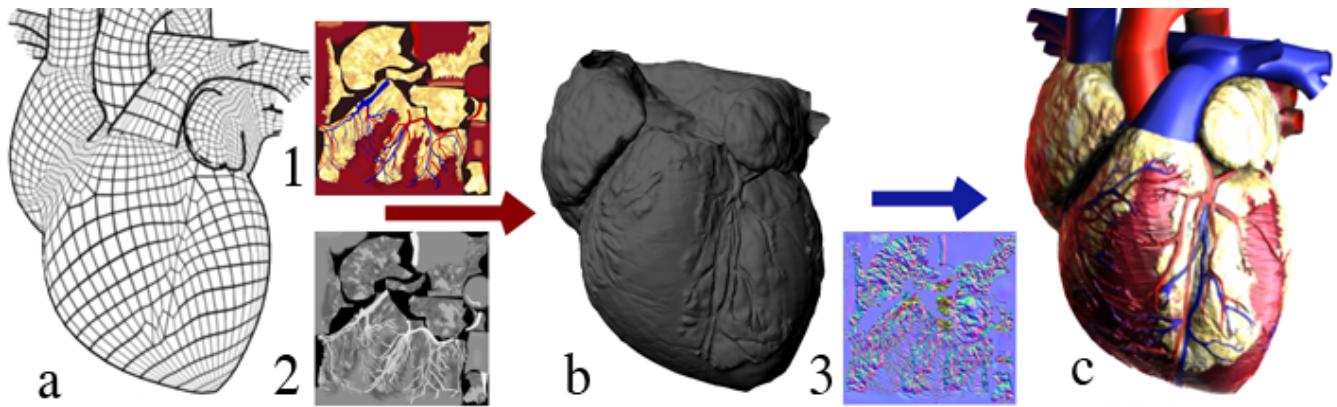


Figure 5: Generation of geometric models. (a) Base mesh and corresponding diffuse (1) and specular (2) texture maps. (b) High resolution polygonal mesh and associated normal map (3). (c) Combined base mesh and normal map, with preserved anatomic details.

3.5 Visual augmentation

The cross sectional 2D ultrasound view is not a very traditional depiction of the heart outside the domain of echocardiography. Most, if not all, medical students will be familiar with an external 3D rendering of the heart, presented with almost ubiquitous red blue colors. Displaying the heart using this traditional representation together with the ultrasound slice will aid the students in contextualizing the familiar anatomy they are seeing in the ultrasound.

A generic 3D model of the heart (Figure 5) has been created using techniques developed in the computer game industry [COM98]. The ventricles, atria, pericardium, mitral, tricuspid, aortic and pulmonary valves, as well as the major arteries and veins have been modelled. Additionally, a generic ultrasound probe is also modelled.

The ultrasound data, as well as the origin and position in world coordinates of the 2D ultrasound slice, correspond to the central elevation plane of the probe and are extracted from the streamed data. The geometric models representing the anatomy of the heart can be intersected with this plane.

The last step of the visual augmentation is image compositing. All elements of the virtual scene have a corresponding layer attached. Each 2D or 3D layer is bound to a renderer unit, which generates the RGBZ image for that particular layer. Based on a predefined layer hierarchy and a stacking order, the layers are combined using the hybrid visibility approach [BRV*10]. This allows for a robust combination of different layers such that the essential features in the scene are preserved and highlighted.

4 Implementation

The ultrasound 3D volumes were acquired using the GE Vivid E9 Dimensions system (GE Vingmed, Horten, Norway) and a 2.5MHz matrix array transducer 4V (GE Vingmed, Horten, Norway), with the healthy volunteers in supine or in the left lateral decubitus position. A gigabit wired connection was established between the scanner and the server by using a D-link DIR 655 router.

The server consisted of a desktop graphics system: NVIDIA GeForce GTX 285, Intel Core i7-2600K Quad Core Processor at 3.40GHz and 16GB RAM. VolumeShop [BG05], the real-time contour tracking library (RCTL) [OTR09] and GPU software for on the fly conversion from ultrasound beam-space coordinates to Cartesian coordinates were running on the server. The HeartPad components

on the server were implemented as extensions to VolumeShop, a visualization framework written in C++ and OpenGL/GLSL, which allows for rapid prototyping.

The real-time contour tracking library is used to fit the coupled deformable model to the current ultrasound volume. Subsequently, the position of the four anatomic landmarks is determined. Based on these positions the transformation matrices in Equations 3 and 5 are computed. For testing purposes, the current RCTL deformable model can also be visualized in the scene (Figure 6.b).

Additionally, a tracking score [0 ... 100%], measuring the quality of the model fit based on the existence of an edge in the ultrasound volume in the vicinity of the fitted model, is computed [SAM*09]. A threshold value of 20% is applied to it. If the tracking score is below the threshold (i.e. no valid ultrasound data or bad positioning of the probe), the fit is deemed inappropriate and the default 3D heart model without any animation is presented to the user. As such the 3D model is constrained to have a reasonable anatomical shape.

The low and high resolution polygon meshes have been created in Autodesk Maya. Corresponding diffuse and shading texture files and normal maps have been created in Adobe Photoshop. For computational efficiency purposes the larger coronary vessels have not been modelled as triangle meshes, instead they were layered into the texture corresponding to the cardiac muscle.

The 2D ultrasound slice data has been extracted by intersecting the 3D OpenGL texture associated with the current ultrasound volume. Tri-linear interpolation is achieved by enabling the GL_LINEAR texture parameter. If the cut plane feature is enabled all the meshes in the scene are intersected with this plane and all fragments situated on the near side of the plane are discarded (Figure 6.c).

The hybrid visibility compositing method of Bruckner et al. [BRV*10] is used for blending. Each layer has an associated renderer instance with an offscreen OpenGL buffer. Before rendering the models, T_{model} (Equation 3) is multiplied with the current GL_MODELVIEW. The model is thus aligned with the current ultrasound data. Additionally, the kinematic model (Figure 4) is applied to the 3D heart mesh.


If dynamic probe tracking is enabled, for both the probe mesh and the ultrasound slice, the current GL_MODELVIEW is also multiplied with $T_{dynamic}$ (Equation 5). As such the dynamic location of these elements with regards to the heart mesh can be visualized interactively in the virtual scene.



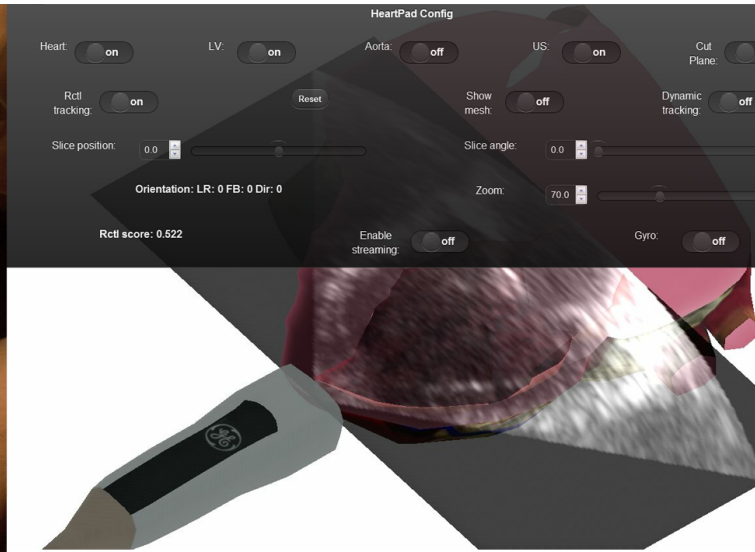a



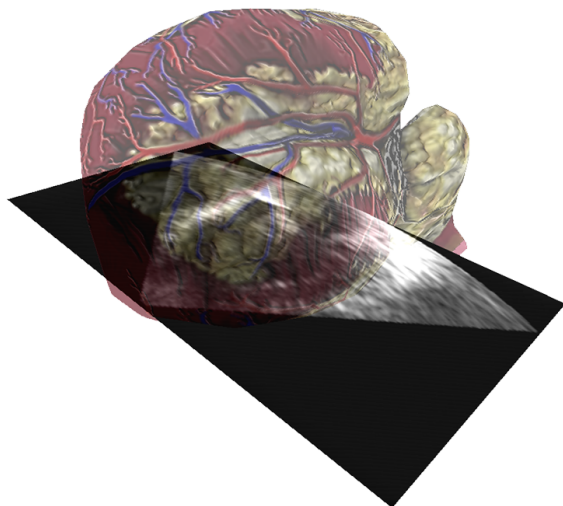
b



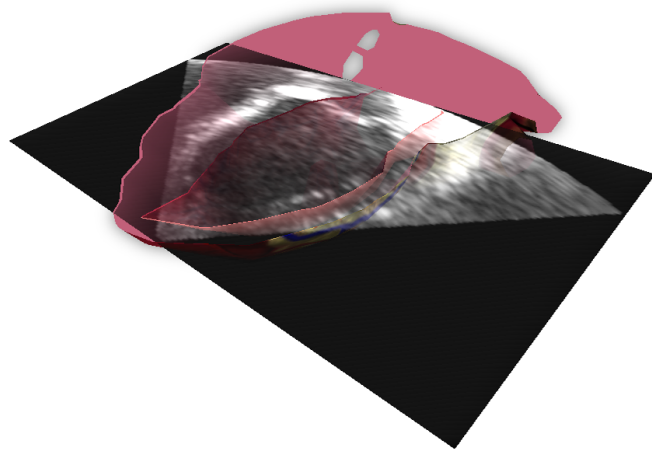
c



d



e



f

Figure 6: (a)-(c) Different visual augmentation techniques tested during live echocardiographic scanning. (d) The user interface on the tablet. (e)-(f) Illustrative visualization combining the 4 chamber echocardiographic view with the heart model.

In our prototype system, the display client is represented by an iPad (Apple Inc.) tablet, which receives a continuous stream of images from the server via a Wi-Fi wireless router (D-link DIR 655). The composite image is displayed in the iPad's default Safari web-browser. The communication protocol relies on JavaScript Object Notation (JSON), while the user interface has been implemented in the jQuery mobile framework 1.1 (Figure 6.d). An articulated arm holder was used in order to stabilize the iPad and in order to easily re-position the device.

5 Results

In order to evaluate the usefulness of our system a feasibility study was carried out. An experienced cardiologist, with over 10 years of clinical practice, performed the scanning on four healthy volunteers. Depending on scanner settings between 6 and 10 volumes per second were achievable.

Streaming of ultrasound data from the scanner to the server required 25% of the theoretical 1Gbps bandwidth on the local wired network. The generation of a Cartesian 3D volume containing 256^3 voxels from beam data took 7 ms on average, on the specified NVIDIA GPU. RCTL fitting times were in the order of 5 ms per volume. The visual augmentation step performs at frame rates above 30 frames/s. The composited images were JPEG compressed before they were streamed to the tablet. The compression level could be manually adjusted.

For the aforementioned frame rates no perceivable latency between the ultrasound data shown on the scanner and the image present on the tablet was observed. Also if a good acquisition quality was achieved and the RCTL tracking score was above the threshold limit of 20%, the movement of the virtual probe visually matched the real probe's movement.

Several visual augmentation schemes were tested, displayed on the HeartPad and presented to the cardiologist (Figure 6). The two that were considered as most useful are presented in detail below.

The image in Figure 6.a illustrates dynamic tracking mode with mesh clipping disabled. A high visibility value is given to the 3D heart model during compositing, while the 2D ultrasound image slice has a lower importance value. This view was most useful for finding a given view, as the imaging plane's anatomical position is clearly visible.

The image in Figure 6.c illustrates dynamic tracking mode with the cut plane enabled. The ultrasound slice has the highest importance value associated in the layer hierarchy and therefore is highlighted in the composited image. The 3D model is sliced and added to underlying layers. This view is useful for refining the quality of a given view.

6 Discussion

After using our prototype during two different scanning sessions, the cardiologist evaluated its usefulness as: *I think this will help students and beginners, they have great problems to correlate anatomy with the image they actually see on the scanner.*

During the feasibility test, it became apparent that in order to achieve a correct viewing angle for some of the standard views, the cardiologist had to use his left hand to hold the probe, which is not the traditional way of working and has to be further investigated. Currently, the 3D data is acquired, but this is not shown in the virtual scene, it is only used for tracking purposes. VolumeShop has support for a variety of real-time volume rendering approaches, thus a volume renderer could be added to the layer hierarchy.

In contrast to other visual guidance systems, our prototype is running on commodity hardware. Furthermore it is specifically designed for ultrasound acquisitions (e.g. cardiac) and can handle large, non-linear deformations between subsequent time frames. By using a modular design, the system is robust enough to handle various usage scenarios, such as in-vivo scanning, remotely guided acquisition or diagnosis, and teaching.

One limitation of probe tracking with the Real Time Contour Tracking Library is that a good ultrasound scan is required in order to determine the current position and orientation of the probe. While this was no problem for experts, it may pose a challenge for an inexperienced user. To address this issue, one can consider the use of optical and/or magnetic tracking systems (e.g. NDI Polaris®) that can accurately measure the 3D position and orientation markers affixed to the ultrasound probe.

7 Conclusions and future work

Combining the 3D heart model with an illustrative representation of the standard viewing planes would be beneficial, as would be the addition of a reference ultrasound image for the current view. That will allow the non-expert user to quickly identify visual cues that are supposed to be imaged.

The addition of the surrounding anatomical structures, such as the lungs, ribs, sternum, and costal cartilage to the virtual scene would help the user explain the causes of potential artifacts present in the image and improve the quality of the acquisition. A more detailed anatomical context could offer guidance during the initial placing of the probe.

To conclude, our prototype system presents, to the user, a high quality, informative visualization together with on-screen rotational and translational feedback. These additions will enable the non-expert user to utilize medical ultrasound without image interpretation difficulties. Additionally, by showing this information on a tablet placed on the patient's chest, an in-situ visualization is achieved and the acquisition protocol is further simplified.

Acknowledgments

The authors would like to thank Dr. Bjørn Olav Haugen for evaluating our prototype and giving useful feedback regarding it.

References

- BERLAGE T., FOX T., GRUNST G., QUAST K.-J.: Supporting ultrasound diagnosis using an animated 3d model of the heart. In *Proceedings of IEEE Multimedia Computing and Systems 1996* (1996), pp. 34–39.
- BAJURA M., FUCHS H., OHBUCHI R.: Merging virtual objects with the real world: Seeing ultrasound imagery within the patient. *ACM SIGGRAPH Computer Graphics* 26, 2 (1992), 203–210.
- BRUCKNER S., GRÖLLER M.: VolumeShop: An interactive system for direct volume illustration. In *Proceedings of IEEE Visualization 2005* (2005), C. T. Silva E. Gröller H. R., (Ed.), pp. 671–678.
- BURNS M., HAIDACHER M., WEIN W., VIOLA I., GRÖLLER M. E.: Feature emphasis and contextual cutaways for multimodal medical visualization. In *Proceedings of EuroVis '07* (2007), pp. 275–282.

- BLUTEAU J., KITAHARA I., KAMEDA Y., NOMA H., KOGURE K., OHTA Y.: Visual support for medical communication by using projector-based augmented reality and thermal markers. In *Proceedings of the International Conference on Augmented Tele-Existence 2005* (2005), pp. 98–105.
- BRUCKNER S., RAUTEK P., VIOLA I., ROBERTS M., SOUSA M., GRÖLLER M.: Hybrid visibility compositing and masking for illustrative rendering. *Computers & Graphics*, 34 (2010), 361–369.
- BIRKELAND Å., SOLTESZOVA V., HÖNIGMANN D., GILJA O. H., BREKKE S., ROPINSKI T., VIOLA I.: The ultrasound visualization pipeline - a survey. *ArXiv e-prints* (2012). arXiv:1206.3975.
- BRATTAIN L., VASILYEV N., HOWE R.: Enabling 3d ultrasound procedure guidance through enhanced visualization. In *Proceedings of the International Conference on Information Processing in Computer-Assisted Interventions 2012* (2012), pp. 115–124.
- COHEN J., OLANO M., MANOCHA D.: Appearance-preserving simplification. In *Proceedings of ACM SIGGRAPH 1998* (1998), pp. 115–122.
- DICKSTEIN K., COHEN-SOLAL A., FILIPPATOS G., MCMURRAY J. J. V., PONIKOWSKI P., POOLE-WILSON P. A., STRMBERG A., VAN VELDHUISEN D. J., ATAR D., HOES A. W., KEREN A., MEBAZAA A., NIEMINEN M., PRIORI S. G., SWEDBERG K., E. S. C. C. F. P. G. C. P. G.: Esc guidelines for the diagnosis and treatment of acute and chronic heart failure 2008. *Eur Heart J* 29, 19 (Oct 2008), 2388–2442. doi:10.1093/eurheartj/ehn309.
- FATTAL R., LISCHINSKI D.: Variational classification for visualization of 3d ultrasound data. In *Proceedings of IEEE Visualization 2001* (2001), pp. 403–410.
- HARDERS M., BIANCHI G., KNOERLEIN B.: Multimodal augmented reality in medicine. In *Proceedings of the International Conference on Universal Access in Human-Computer Interaction 2007* (2007), pp. 652–658.
- HUNG J., LANG R., FLACHSKAMPF F., SHERNAN S., MCCULLOCH M., ADAMS D., THOMAS J., VANNAN M., RYAN T.: 3d echocardiography: a review of the current status and future directions. *Journal of the American Society of Echocardiography* 20, 3 (2007), 213–233.
- HÖNIGMANN D., RUISZ J., HAIDER C.: Adaptive design of a global opacity transfer function for direct volume rendering of ultrasound data. In *Proceedings of IEEE Visualization '03* (2003), pp. 489–496.
- KALKOFEN D., MENDEZ E., SCHMALSTIEG D.: Comprehensive visualization for augmented reality. *IEEE Transactions on Visualization and Computer Graphics* 15, 2 (2009), 193–204.
- KALKOFEN D., REITINGER B., RISHOLM P., BORNIAK A.: Integrated medical workflow for augmented reality applications. *Workshop on Augmented* (2006).
- LE BELLEGO G., BUCKI M., BRICAULT I.: Using a smart phone for information rendering in computer-aided surgery. In *Proceedings of the International Conference on Human-Computer Interaction 2011* (2011), pp. 202–209.
- LINTE C., MOORE J., WILES A., WEDLAKE C., PETERS T.: Virtual reality-enhanced ultrasound guidance: a novel technique for intracardiac interventions. *Computer Aided Surgery* 13, 2 (2008), 82–94.
- NELSON T., ELVINS T.: Visualization of 3d ultrasound data. *IEEE Computer Graphics and Applications* 13, 6 (1993), 50–57.
- ORDERUD F., TORP H., RABBEN S.: Automatic alignment of standard views in 3d echocardiograms using real-time tracking. In *Proceedings of the SPIE 7265* (2009), p. 72650D.
- ØYE O. K., ULVANG D. M., GILJA O. H., HAUSER H., VIOLA I.: Illustrative couinaud segmentation for ultrasound liver examinations. In *Smart Graphics*, vol. 6815 of *Lecture Notes in Computer Science*. Springer Berlin / Heidelberg, 2011, pp. 60–77.
- PETERSCH B., HÖNIGMANN D.: Blood flow in its context: Combining 3D B-mode and color Doppler us data. *IEEE TVCG* 13, 4 (2007), 748–757.
- PIEPER S., WEIDENBACH M., BERLAGE T.: Registration of 3d ultrasound images to surface models of the heart. *Proceedings of the Interface to Real & Virtual Worlds* (1997), 211–213.
- SNARE S., AASE S., MJLSTAD O., DALEN H., ORDERUD F., TORP H.: Automatic real-time view detection. In *Ultrasonics Symposium (IUS), 2009 IEEE International* (sept. 2009), pp. 2304–2307. doi:10.1109/ULTSYM.2009.5441530.
- STETTEN G., CHIB V.: Overlaying ultrasonographic images on direct vision. *Journal of Ultrasound in Medicine* 20, 3 (2001), 235–240.
- STETTEN G., CHIB V., TAMBURRO R.: Tomographic reflection to merge ultrasound images with direct vision. In *Proceedings of the IEEE Workshop on Applied Imagery Pattern Recognition* (2000), pp. 200–205.
- STÜDELI T., KALKOFEN D., RISHOLM P., ALI W., FREUDENTHAL A., SAMSET E.: Visualization tool for improved accuracy in needle placement during percutaneous radio-frequency ablation of liver tumors. *Proceedings of the SPIE 6918* (2008), 69180B.
- STATE A., LIVINGSTON M., GARRETT W., G. H., WHITTON M., PISANO E., FUCHS H.: Technologies for augmented reality systems: Realizing ultrasound-guided needle biopsies. In *Proceedings of ACM SIGGRAPH 1998* (1998), pp. 439–446.
- SAKAS G., SCHREYER L.-A., GRIMM M.: Preprocessing and volume rendering of 3D ultrasonic data. *IEEE Computer Graphics and Applications* 15, 4 (1995), 47–54.
- TANG S. L., KWONG C. K., TEO M. Y., SING N. W., LING K. V.: Augmented reality systems for medical applications. *IEEE engineering in medicine and biology magazine : the quarterly magazine of the Engineering in Medicine & Biology Society* 17, 3 (1998), 49–58.
- VARANDAS J., BAPTISTA P., SANTOS J., MARTINS R., DIAS J.: Volus—a visualization system for 3d ultrasound data. *Ultrasonics* 42, 1-9 (2004), 689–694.
- VIOLA I., NYLUND K., ØYE O. K., ULVANG D. M., GILJA O. H., HAUSER H.: Illustrated ultrasound for multimodal data interpretation of liver examinations. In *Proceedings of VCBM'08* (2008), pp. 125–133.